Drug Induced Enteropathy , Colopathy

Dr Ehsani Ardakani

Gastroenterology And Liver Diseases , Shahid Beheshti University Of Medical Science , Tehran , Iran

13 Feb 2025

Introduction

- **Definition**
- Gastrointestinal damage or disease caused by the use of various medications , causing

✓Inflammation , Malabsorption , Diarrhea and Structural changes

Incidence

- Relatively uncommon
- Important to recognize due to associated morbidity
- A large number of drugs have been implicated as cause of chronic diarrhea

✓At least 700 drugs

✓Through a number of different **pathophysiologic mechanisms**

- Sometimes overlapped

Clinical Presentation

- Diarrhea , watery , bloody
- Bloating and nausea
- Abdominal pain , cramps
- Weight loss
- Malabsorption
- Death

Differential Diagnosis

- IBD
- IBS
- Infectious Enteritis
- SIBO
- Microscopic Colitis
- Celiac Dis
- Ischemic colitis
- GVHD
- ….

Diagnostic Workup

- **Clinical History**

✓Through medical review

✓Onset of symptoms

✓R/O other causes

- **Laboratory tests**

✓S/E , S/C , CBC , CRP, ESR , FCP, LFT , Electrolyte ,…

- **Endoscopy and biopsy**

Different mechanisms underlying Enteral damage

- **Functional damage**

✓Abnormalities in any of the mechanisms involving

- Digestion (maldigestion) and/or
- Absorption (malabsorption)

✓GI motility disturbances

✓Alterations in the water and electrolyte absorption and/or secretion mechanisms

✓Altered microbiota and/or microbiome (dysbiosis)

Different mechanisms underlying Enteral damage

- **Mucosal Damage : Microscopic or overt**

✓Direct contact of the drug

✓Ischemic-related damage

✓Systemic inflammatory

✓Immune mediated mechanisms

- May affect different portions of the small intestine, colon, or both

Pathophysiologic mechanisms of enteropathy according to drug type

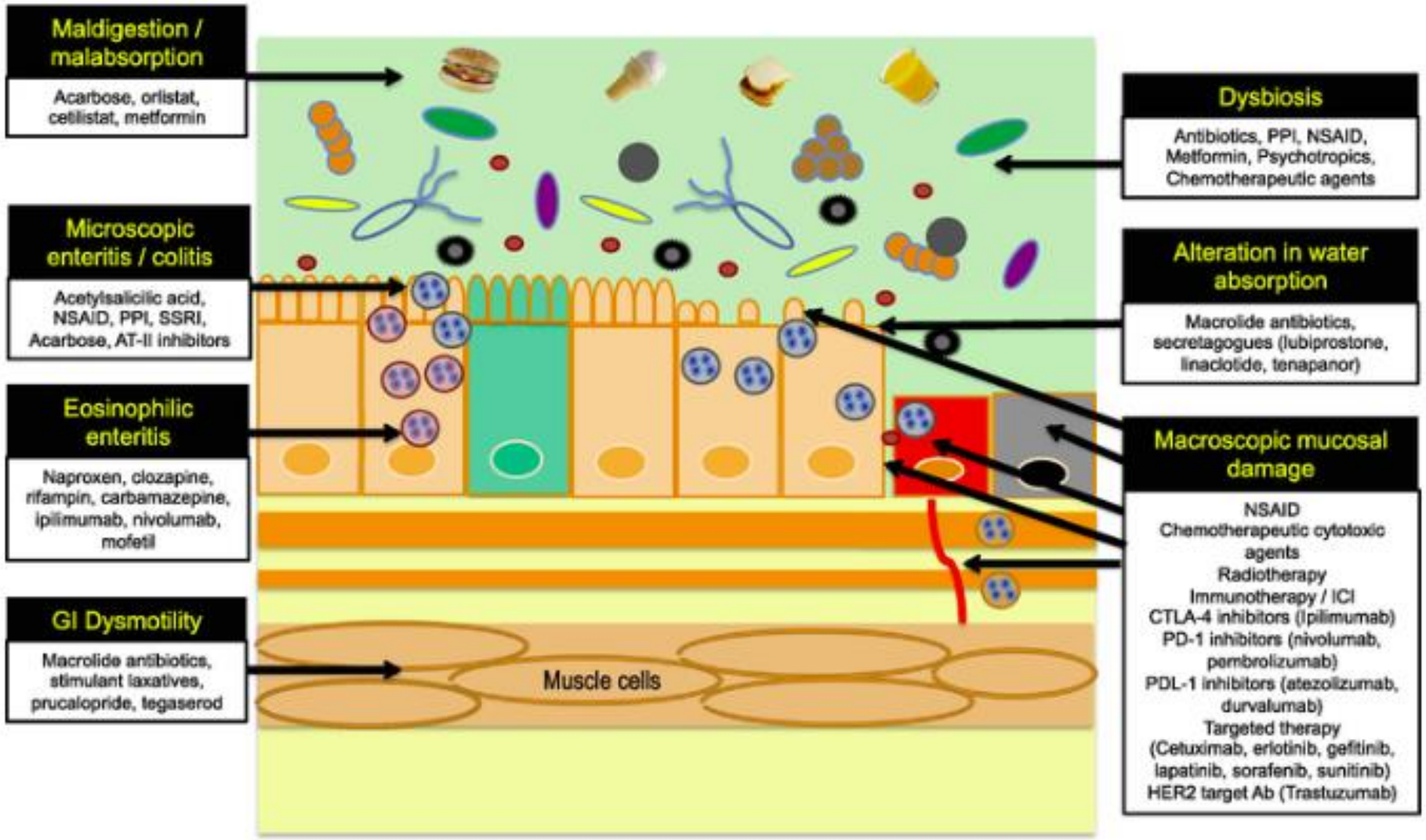

Maldigestion and malabsorption

- **Acarbose**

✓ Inhibits alpha-glucosidase activity in the brush border membrane of the small intestine, an essential enzyme for digestion of starch, maltose and sucrose, **delaying glucose absorption** from carbohydrate food

- **Orlistat**

✓ Inhibitor of gastric and pancreatic lipoprotein lipases, resulting in inhibition of up to 30% of **dietary fat absorption**, decreasing fat mass, as well as levels of the regulatory hormone leptin as patients lose weight

- **Metformin**

✓ Altered transport of serotonin, histamine or both, increased enterocyte lactate concentration, dysbiosis, increased bile acid pool in the distal ileum, bile acid receptor activation, and increased conversion from primary to secondary bile acids, which are pro-secretory, leading to increased water and electrolyte luminal secretion and **motility alterations**

✓ **Cholestyramine**

Alterations in motility and water absorption/secretion

- **Antibiotics**, particularly

✓Macrolides (e.g., azithromycin, clarithromycin, erythromycin)

- Act as motilin analogues

- **Laxatives**

✓Cause diarrhea through a number of mechanisms according to pharmacologic type

Dysbiosis

- **Antibiotic**

✓5 and 49% of antibiotic users develop diarrhea during or after treatment

- **Risk factors for AAD**

✓Increasing age, therapy with more than 1 antibiotic, clindamycin use, long-term antibiotic use, and concomitant PPI use

- **Mechanisms** associated with DAA

✓Alteration of microbiota/microbiome

✓Direct effect over intestinal mucosa and motility

Dysbiosis

- **Proton pump inhibitors** (PPI)
- **NSAID**
- **Immunotherapy** , Different mechanisms

✓Main pathophysiologic mechanism

- Dysbiosis
- Mucosal damage

- **Anti-psychotics**, **antidepressants** and other mood stabilizers, **statins**, **antiarrhythmics**, and **anticoagulants?**

Mucosal damage

- **Enteropathy** , Small intestine and colon

✓20–40% of all GI side effects

- **Mechanisms**

✓**Direct cytotoxic damage** on the intestinal mucosa resulting in several degrees of inflammation

- Mucositis, erosions and/or ulcers, hemorrhagic enteritis

✓**Alterations in permeability**

✓**Protein-loss associated enteropathy**

✓**Ischemic damage, either caused by**

- Long-standing vasoconstriction and/or thrombosis

Drugs associated with diarrhea

Macroscopic enteral mucosal damage

- **NSAID**
- Pathophysiology : complex

✓COX inhibition and topical effect

✓Interactions with bacteria and bile acids

✓Overexpression of pro-inflammatory cytokines

- **Potassium supplements, OCP, Cytotoxic drugs** (MTX and chemotherapeutic agents)

✓Mucositis ,small and large intestine mucosal disease

✓Vasoconstriction and ischemia

Drugs associated with diarrhea
Microscopic enteral mucosal damage

- Pathophysiology mechanisms
- Not clear

✓Activation of the **immune system** in response to exposure to luminal antigenic factors, including **drug-itself, metabolites, bile-acids**

Eg:Allopurinol , sulfasalazine

✓May be associated with changes in **microbiota** linked to long-term drug use, such as in PPI

Drugs linked to Microscopic colitis

- Aspirin
- NSAID
- PPI
- SSRI, particularly sertraline
- Clozapine
- Ticlopidine
- Flavonoids
- Acarbose ,…

Eosinophilic Enteritis , Colitis

- High eosinophilic infiltrate in the gut wall
- Clozapine, Naproxen, Carbamazepine, Rifampicin

✓Increased eosinophilic infiltrate in the distal ileum and colon

- Anti-CTLA-4 check-point inhibitor

✓Lpilimumab and the anti-PD1 Nivolumab

- Mycophenolate mofetil

▪ May affect both small bowel and colon

✓Causing an eosinophilic-associated damage

▪ Similar to those of acute GVHD

Angiotensin II receptor inhibitors (AT-II RI)

- Olmesartan
- Other AT-II RI

✓Associated with **different degrees of enteropathy**

- A systematic review included 248 cases, most of which were associated with olmesartan **(94%),** however telmisartan, irbesartan, valsartan, losartan and eprosartan also were reported to be associated with various degrees of enteropathy

✓Negative serology in most cases

✓71% had a positive HLA-DQ2 or DQ-8

Immune checkpoint inhibitor-induced diarrhea/colitis

- Among irAEs, ICPI-induced colitis/diarrhea

✓Oncologists / Gastroenterologists or endoscopists

- ICPI-induced diarrhea occurs

✓After an average of three infusions

✓Can develop at any time , even after discontinuation of ICPIs

ICPI-induced diarrhea/colitis

- Wide ranges of its onset timing

✓Difficult to predict the development of ICPI-induced diarrhea/colitis

- Other drugs may influence the process

✓NSAIDs, antibiotics, previous anticancer drugs

- Before patients have symptoms

✓Difficult to predict the development of colitis

Immunological pathways underlying the pathogenesis of ICIs colitis

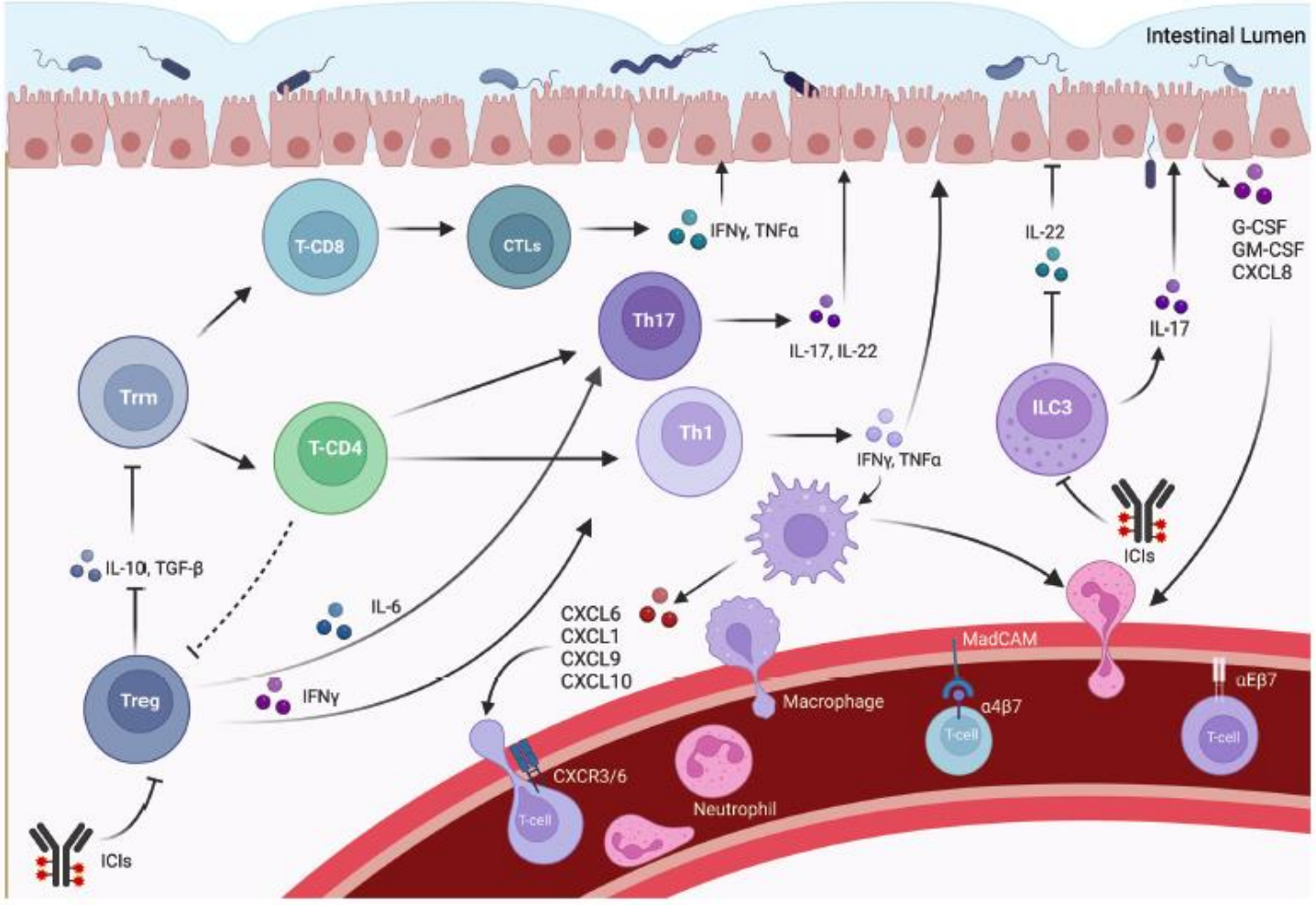

Downloaded from https://academic.oup.com/ibdjournal/article/3

Downloaded from https://academic.oup.com/ibdjournal/article/30/6/1018/7295305 by guest on 06 February 2025

- Tissue-resident memory T cells (Trm) are recruited and differentiate in cytotoxic effector CD8+ T cells and CD4+ T cells, due to the absence of IL-10 produced by regulatory T cells (Treg). Moreover, Treg usually show gene expression related to an IFNγ -mediated pro-inflammatory Th1-type effect. IL-6 shifts TGF-beta-mediated differentiation of CD4+ naïve cells into Tregs towards Th17 differentiation, even reprogramming Tregs into Th17 cells. The lack of IL-10, enhanced by the production of IL-6 lead to the activation of Th17 cells, which, in turn, produce the proinflammatory IL-17, leading to the development of colitis. Through stimulation of intestinal epithelial cells (IEC) and increased production of G-CSF, GM-CSF, and CXCL-8, IL-17 is also implicated in the recruitment and infiltration of neutrophils and macrophages from systemic circulation. Additionally, lymphocyte recruitment is mediated by the interaction between integrin α4β7, but also αEβ7 on CD8+ lymphocytes and MadCAM on the intestinal endothelium. Macrophages also fulfil a significant role in T-cell recruitment during ICI colitis pathogenesis, mainly through IFN-induced expression of ligands of CXCR3 (CXCL9 and CXCL10) and CXCL-1. The CXCR6 -CXCL16 pair is another crucial couple responsible of T-cell recruitment. Furthermore, the severity of ICI colitis is positively correlated with the number of group 3 innate immune cells (ILC3) that, under ICIs therapy, switch from the production of the anti-inflammatory interleukin-22 (IL-22), which maintains intestinal homeostasis, to IL-17 production.
- Abbreviations: Trm, Tissue-resident memory T-cell; Treg, Regulatory T cell; T-CD, T cell Cluster of Differentiation; CTLs, Cytotoxic T lymphocytes; Th, T helper cell; ILC3, Type 3 innate lymphoid cell; IFN-γ - Interferon gamma; TNF-α, Tumor necrosis factor-alpha; IL, Interleukin; G-CSF, Granulocyte ColonyNStimulating Factor; GM-CSF, Granulocyte Macrophage Colony Stimulating Factor; CXCL, C-X-C-Motif Chemokine Ligand; ICIs, Immune checkpoint inhibitors.

Wang et al observed that endoscopic inflammatory findings were found in more than 80% of patients with ICPI-induced diarrhea/colitis

- Common endoscopic inflammation findings

✓Exudates

✓Loss of vascular pattern

✓Granular or Edematous mucosa

✓Patch or diffuse erythema

✓Aphthous lesions and ulcerations

Inflammatory changes, pathological changes

- Dominantly more diffuse than patchy
- Patchy distribution was endoscopically observed in

✓Half of the patients with diarrhea

- Resemble those of IBD

✓Particularly with UC

Histologic features of ICPI-associated colitis

- Nonspecific
- Can mimic other type of colitis

✓Infectious colitis, IBD, GVHD, and other drug-induced colitis

- ICPI-associated colitis

✓Lacks the features of chronicity that characterize IBD

- Expanded lamina propria by lymphoplasmacytic infiltrate

✓Discriminate from GVHD although increased crypt apoptosis is the *sine qua non*e

Endoscopic findings caused by an immune checkpoint inhibitor

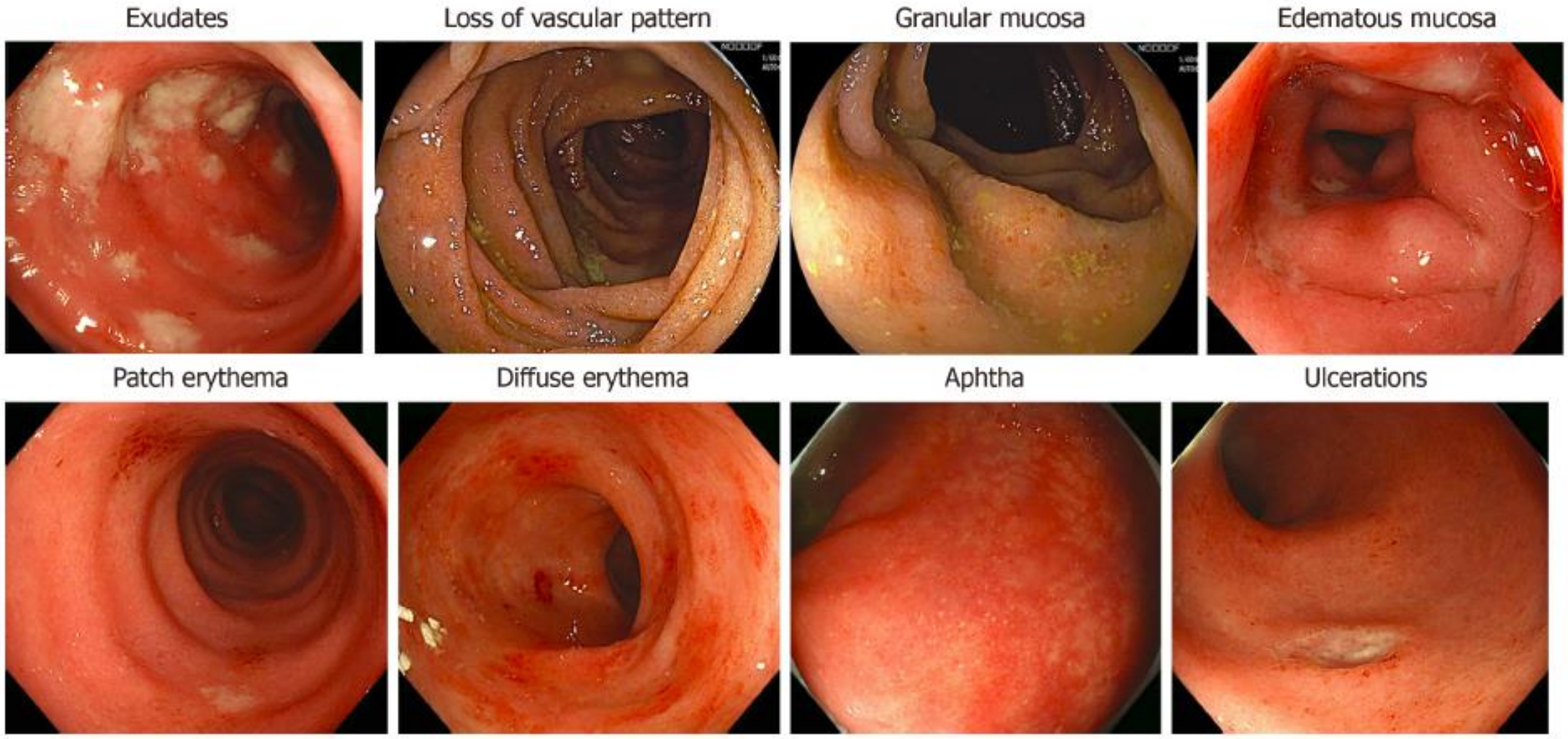

Endoscopic patterns of ICIs colitis.
In panel A, Crohn's like pattern is observed, characterized by oedematous, hyperaemic mucosa with extensive ulcerations, some with a fibrinous base, and pseudo-polyps.
In panel B, there is a UC like pattern; the mucosa appears hyperaemic in places with isolated erosions, it is edematous, with disappearance of the submucosal vascular pattern

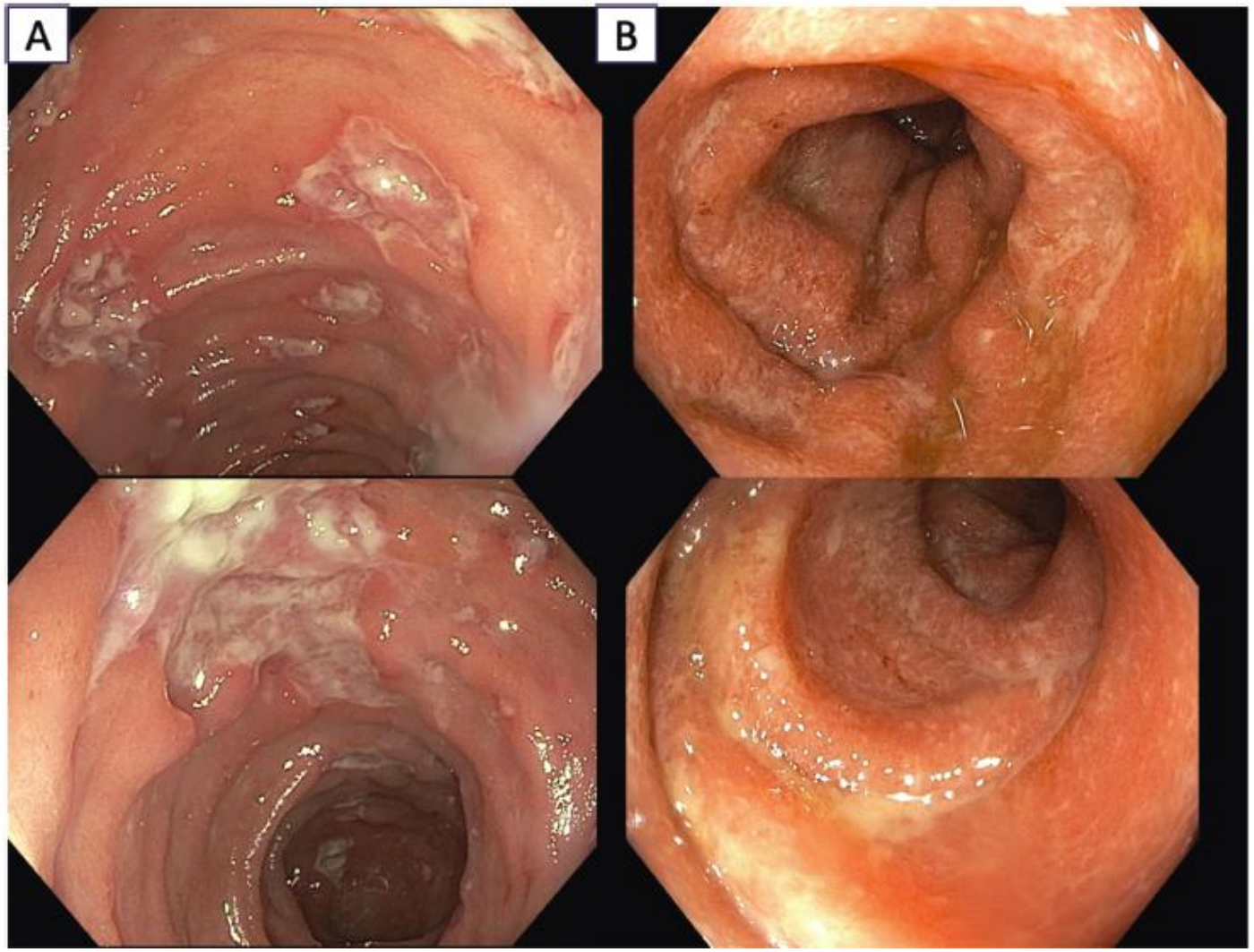

Programmed cell death protein 1 inhibitor-associated colitis

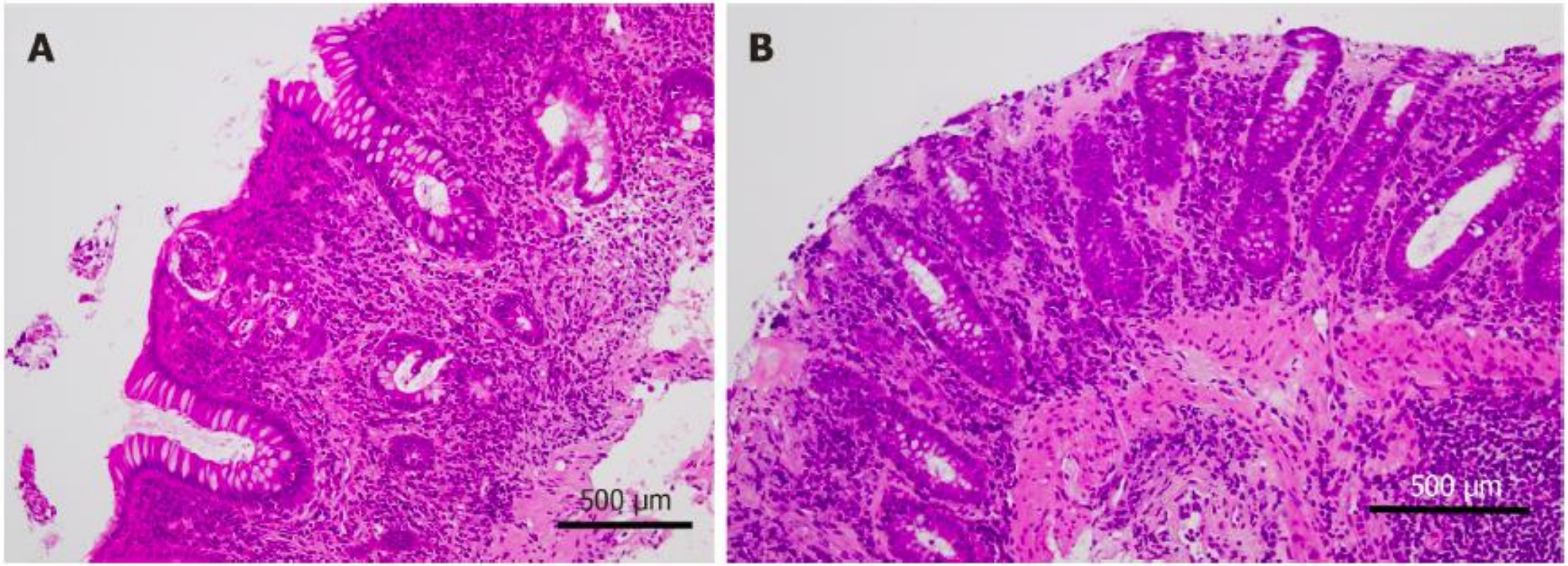

Programmed cell death protein 1 inhibitor-associated colitis

- A: This colon biopsy reveals lamina propria expansion by lymphoplasmacytic infiltrate.Crypt distortion, crypt abscess, and cryptitis are prominent in the mucosa. In the stroma, a significantly increased eosinophilic infiltrate is observed **(IBD like)**
- B: In another case of immune checkpoint inhibitors-related colitic mucosa, a subluminal collagen band thickening is prominent as observed in **collagenous colitis**

Definition of diarrhea and colitis based on Common Terminology Criteria for Adverse Events

CTCAE Term	Definition	Grade 1	Grade 2	Grade 3	Grade 4	Grade 5	CTCAE v5.0 Change
Diarrhea	A disorder characterized by an increase in frequency and/or loose or watery bowel movements	Increase of < 4 stools per day over baseline; mild increase in ostomy output compared to baseline	Increase of 4-6 stools per day over baseline; moderate increase in ostomy output compared to baseline; limiting instrumental ADL	Increase of ≥ 7 stools per day over baseline; hospitalization indicated; severe increase in ostomy output compared to baseline; limiting self-care ADL	Life-threatening consequences; urgent intervention indicated	Death	Clarification: Grade 2, 3, Definition
Colitis	A disorder characterized by inflammation of the colon	Asymptomatic; clinical or diagnostic observations only; intervention not indicated	Abdominal pain; mucus or blood in stool	Severe abdominal pain; peritoneal signs	Life-threatening consequences; urgent intervention indicated	Death	Addition: Navigational note; Clarification: Grade 3

Management of ICPI-associated colitis

- Grade 1 diarrhea/colitis

✓Antidiarrheal drugs and/or oral hydration with electrolyte substitution can be initiated. In cases of

- Persistent or grade 2 or higher diarrhea or rectal bleeding

▪ Confirm colitis

✓R/O GI infection by testing for stool leukocytes, stool cultures, IBD, or tumor-related GI symptoms

✓*Clostridioides difficile* toxin and/or antigen test, CMV PCR, and tests for stool ova and parasites should be carried out

Management of ICPI-associated colitis , cont…

- Sigmoidoscopy or colonoscopy and mucosal biopsy
- Confirm colitis , R/O GI metastasis because it is not uncommon in lung cancer or melanoma.
- If ICPI-induced colitis is diagnosed

✓Oral steroid is recommended.

- In the case of grade 3/4 diarrhea/colitis or persistent symptoms after oral steroids for several days

✓Intravenous steroids should be considered

Management of ICPI-associated colitis , cont…

- If patients respond to intravenous steroids within several days

✓Switched to oral steroids and tapered

- If they fail to respond to steroid infusion

✓Anti-TNF-α should be considered

✓Vedolizumab was a safer and more theoretic alternative than anti-TNF in patients with steroid-dependent or partially refractory ICPI-induced enterocolitis

Chemotherapy related diarrhea Mechanisms

- **Secretory and Osmotic Diarrhea**

✓Direct cytotoxic effects on the enterocytes and endothelial cells

- Reducing the surface area available for nutrient and water absorption due to harm to the villi
- Rebound crypt hyperplasia, where immature crypt cells ascend to the tip of the villus, impairing the efficient absorption of water and leading to diarrhea
- Damage to the brush border enzyme system within the epithelium can cause osmotic diarrhea due to inadequate digestion

- **Dysbiosis**
- **Motility changes**
- **Others** , Eg : Mesenteric ischemia from thrombosis and/or vasoconstriction

- Rx with monoclonal antibody against VEGE

Chemotherapeutics drugs Most often involved in CRD

- 5-FU
- Capecitabine
- Irinotecan
- Oxaliplatin
- Gemcitabine
- Anti-EGFR monoclonal antibody , Cetoximab
- Small molecule inhibitors of VEGER ,Sorafinib

Colitis syndromes in Chemotherapeutics drugs

- Neutropenic enterocolitis (Typhlitis) in Leukemia patients , undergoing induction Rx
- Ischemic colitis
- C Diff associated colitis
- Lymphocytic colitis
- Ritoximab , an anti-CD20 monoclonal antibody

✓New onset UC or exacerbation of preexisting colitis

Mycophenolate

- Persistent diarrhea is the most common adverse reaction
- In one study :75 % of 85 patients receiving Mycophenolate had GI symptoms
- Histopathologic changes suggestive of

✓IBD : 28%

✓GVHD : 19%

✓Ischemia : 3%

✓Self limited colitis : 16%

Mucosal thickening in stomach , small bowel and colon in Mycophenolate GI toxicity

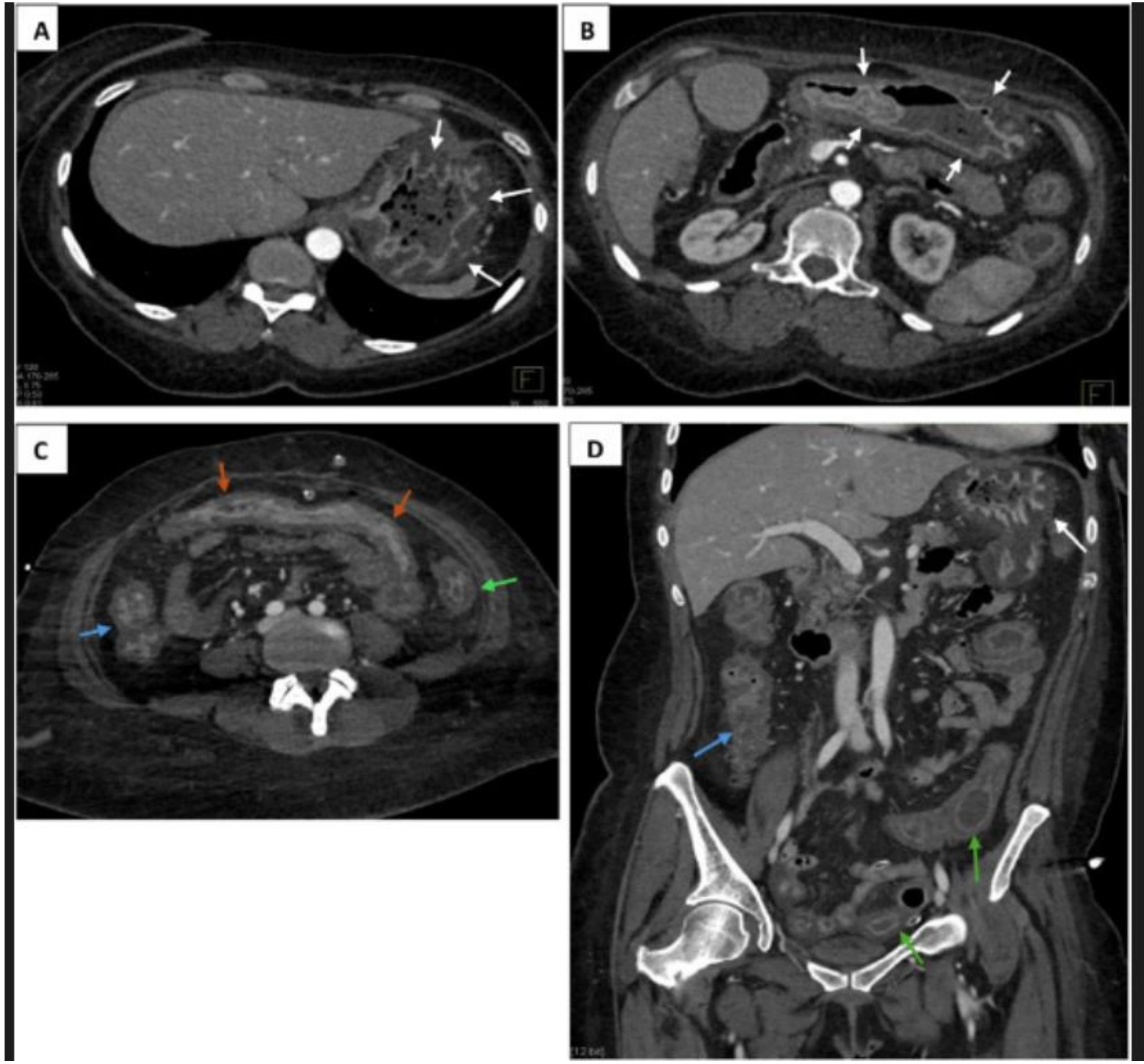

Ulceration , edema , erythema in colon mucosa in Mycophenolate usage

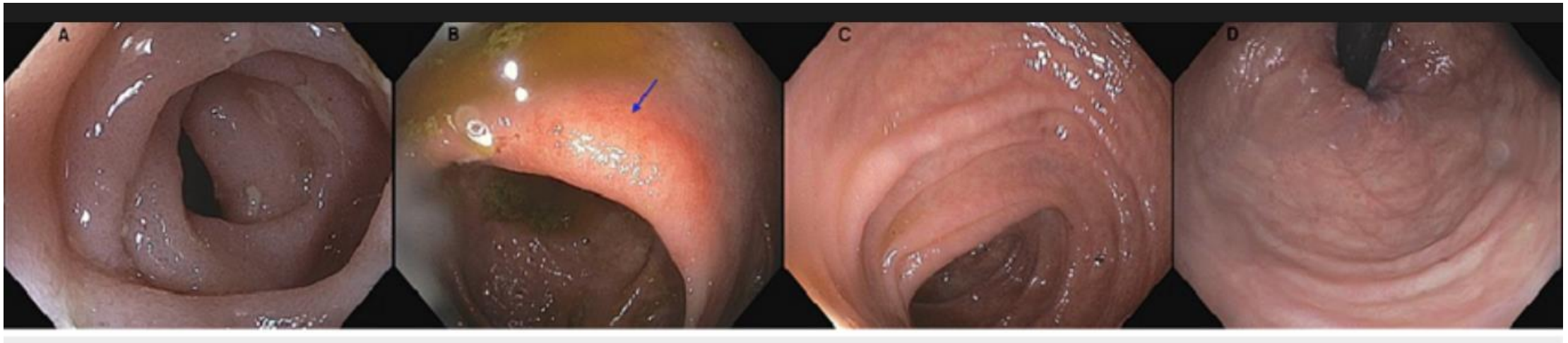

Ulceration , edema ,
erythema ,
coarse appearing
colon mucosa
in Mycophenolate
usage

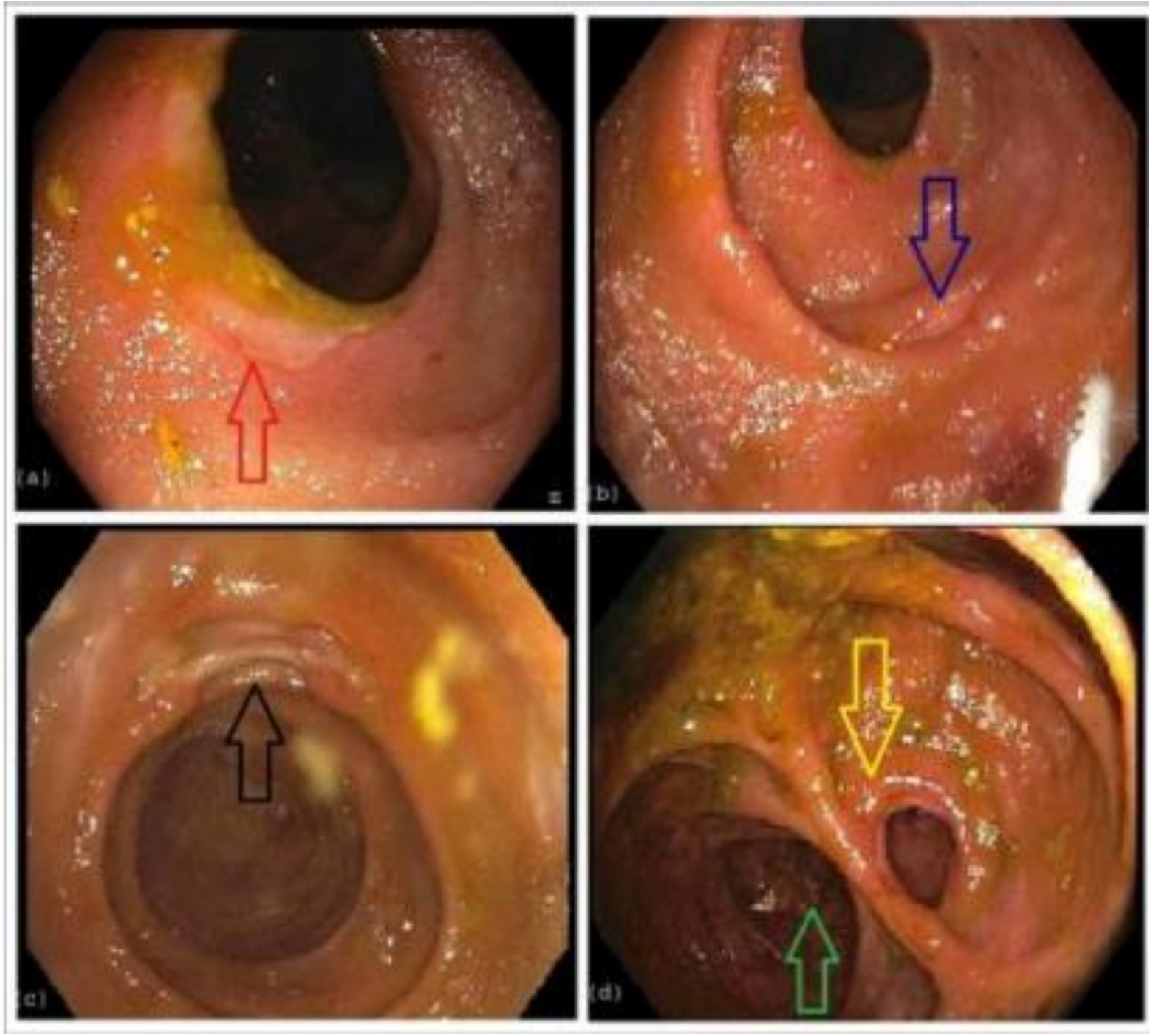

Crypt architectural distortion ,
Lamina propria eosinophils infilteration ,
Crypt apoptosis

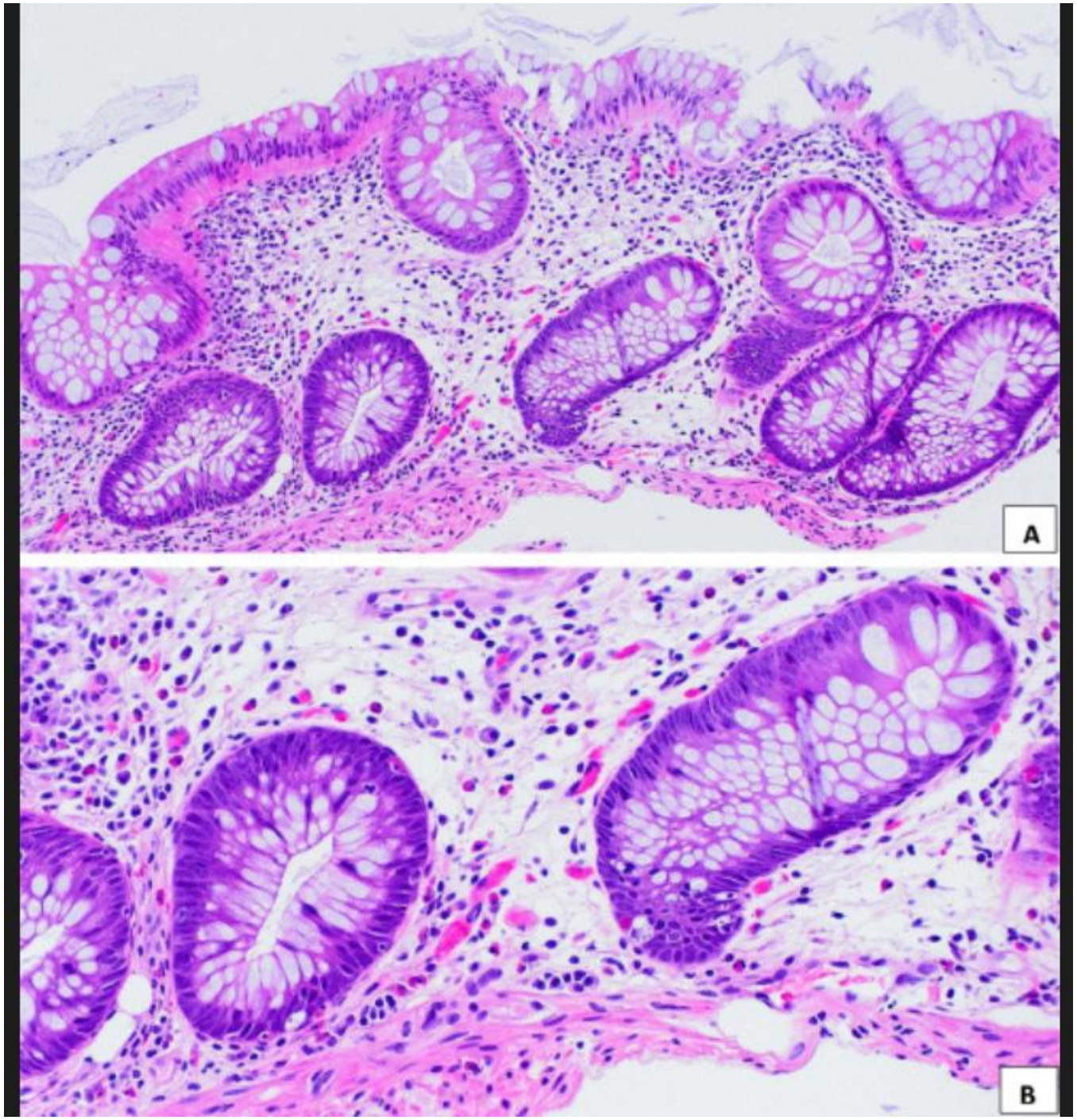

Cyclophosphamide (CPA) associated enteropathy
Computed tomography scans of the abdomen
Diffuse wall thickening of the stomach, small intestine, and colon

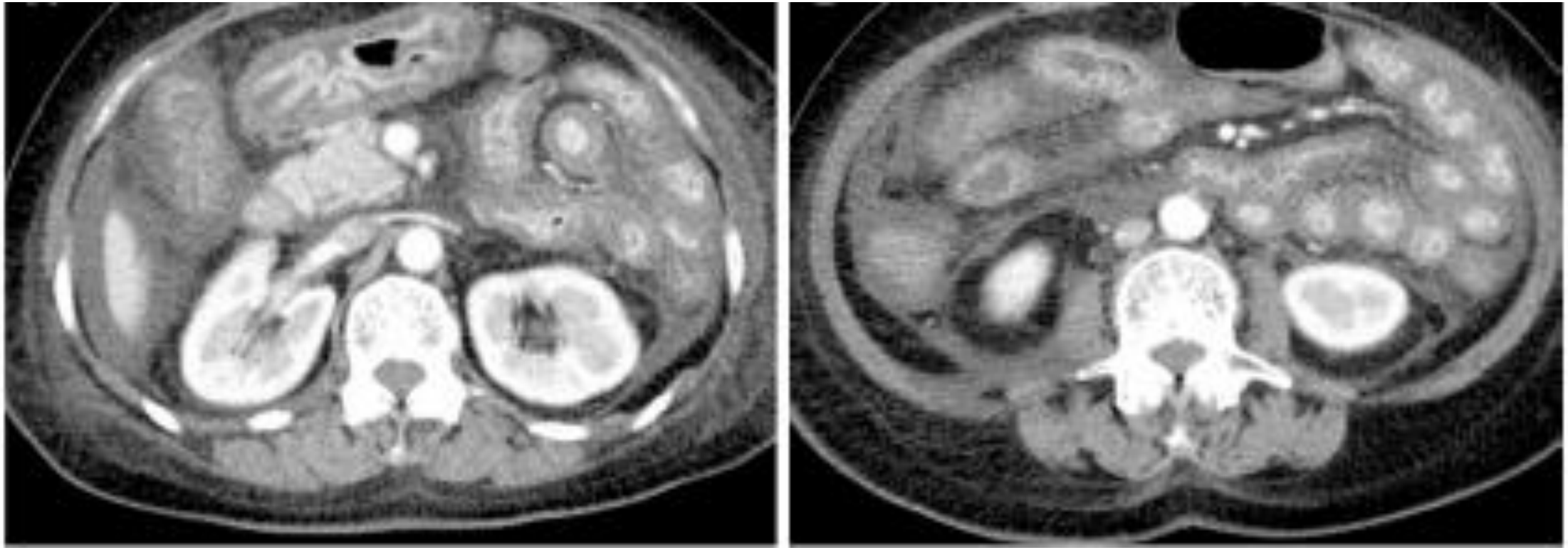

Upper gastrointestinal endoscopy images showing diffuse erosion , nodularity throughout the descending duodenum in CPA associated enteropathy

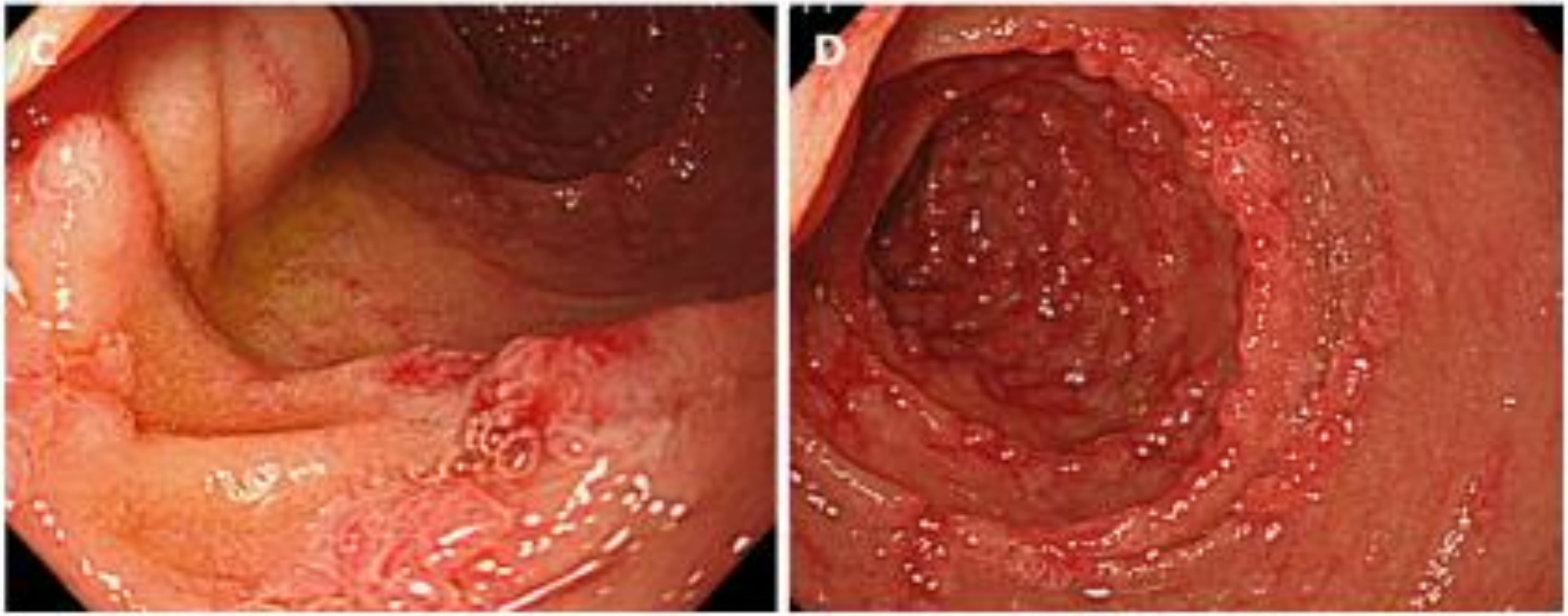

Colonoscopy images showing generalized edema and depression with erythema mainly at the end of the ileum in CPA associated enteropathy

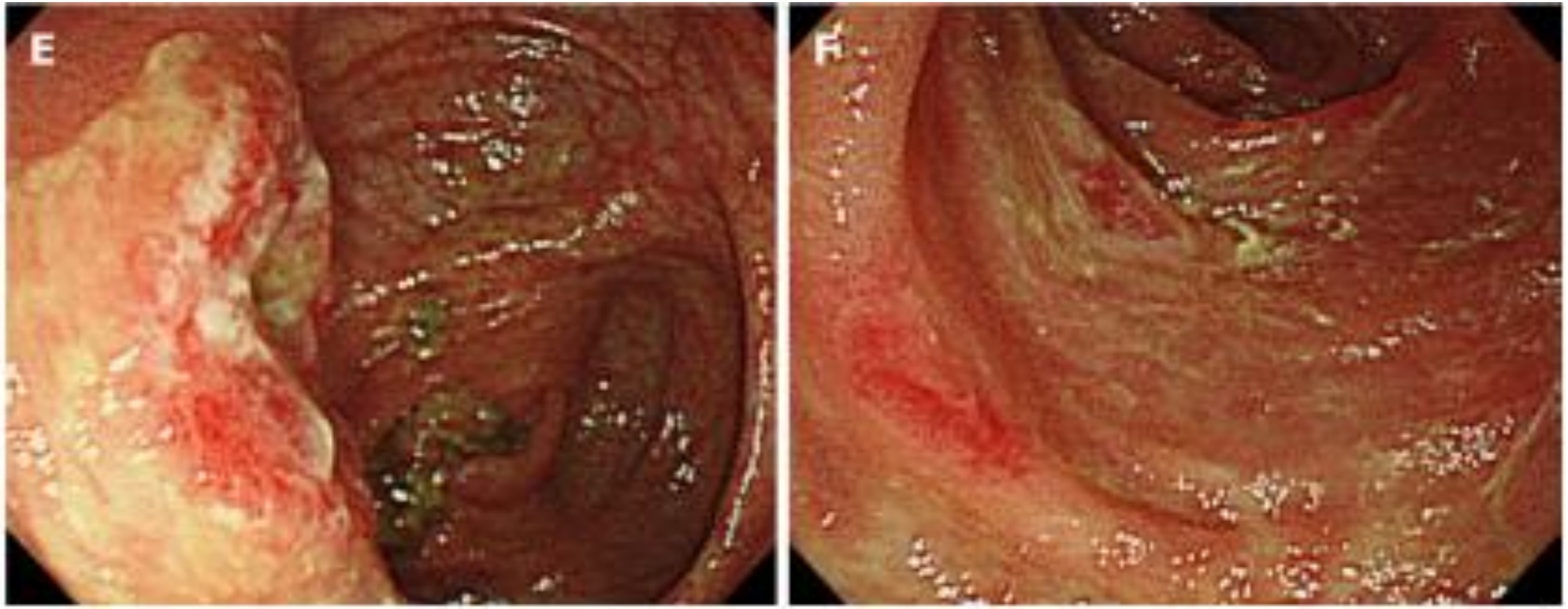

Caecum and ileocecal valve with mucosal ulcers and fibrous stenosis in RTX treated patient



Management of acute chemotherapy related diarrhea

- Assessment

✓Admission in hospital for grade 1 , 2 complicated diarrhea or grade 3 or 4

✓Non-pharmacologic measures

✓Pharmacologic therapy

- Loperamide
- Octreotide

Takeaways message

- Drug induced enteropathy is not preventable
- Early diagnosis and management are critical to prevent complications
- Diagnosis is by the exclusions
- Discontinuation of the offending agent is the cornerstone of treatment in severe and problematic cases
- There is no prophylaxis drugs
- Awareness among clinicians is essential for prompt recognition and successful treatment

ELSEVIER

Regístrese

MI CUENTA

Revistas Cursos Call for papers Artículos más leídos Colecciones +

Gastroenterología y Hepatología (English Edition)

Buscar artículos

Inicio > Gastroenterología y Hepatología (English Edition) > Rituximab-associated colitis

Inicio Todos los contenidos Publique su artículo Acerca de la revista Métricas English

Artículo anterior | Artículo siguiente

Información de la revista

Vol. 42. Núm. 4.
páginas 251-252 (abril 2019)

Lee este artículo en Español Exportar referencia Compartir Imprimir Descargar PDF

SCIENTIFIC LETTER

DOI: 10.1016/j.gastre.2019.03.006

Acceso a texto completo

Este artículo ha recibido
3127 Visitas

Rituximab-associated colitis

Colitis asociada a rituximab

ISSN 2150-5330 (online)

World Journal of *Gastrointestinal Pathophysiology*

World J Gastrointest Pathophysiol 2019 September 10; 10(2): 11-35



Gastroenterology 2021;160:437–444

CLINICAL PRACTICE UPDATES

AGA Clinical Practice Update on the Evaluation and Management of Seronegative Enteropathies: Expert Review

Maureen M. Leonard,[1,2] Benjamin Lebwohl,[3] Alberto Rubio-Tapia,[4] and Federico Biagi[5]

[1]Center for Celiac Research and Treatment, Division of Pediatric Gastroenterology and Nutrition, MassGeneral Hospital for Children, Boston, Massachusetts; [2]Harvard Medical School, Boston, Massachusetts; [3]Celiac Disease Center, Columbia University Irving Medical Center, New York, New York; [4]Division of Gastroenterology, Hepatology, and Nutrition, Digestive Disease and Surgery Institute, Cleveland Clinic, Cleveland, Ohio; and [5]Clinical Scientific Institutes Maugeri Scientific Institute for Research, Hospitalization and Healthcare, Gastroenterology Unit of Pavia Institute, University of Pavia, Italy

DESCRIPTION: Our aim was to provide a consensus statement for the best approaches for diagnosis and management of patients with suspected enteropathy, but negative results from serologic tests for celiac disease (seronegative enteropathy). **METHODS:** We collected findings from published cohort, case–control, and cross-sectional studies of diagnosis and case series and descriptive studies of management of patients believed to have celiac disease or other enteropathies unrelated to gluten, but negative results from serologic tests. **BEST PRACTICE ADVICE 1:** Review histologic findings with experienced pa- should be treated with budesonide. **CONCLUSIONS:** These best practice guidelines will aid in diagnosis and management of patients with suspected celiac disease, but negative results from serologic tests.

Keywords: GFD; Celiac; CeD; tTg.

Seronegative enteropathy, characterized by some degree of villous atrophy and negative tissue trans-

Clinical Gastroenterology and Hepatology 2020;18:1393–1403

Management of Patients With Immune Checkpoint Inhibitor-Induced Enterocolitis: A Systematic Review

Michael Collins,[*,‡,§] Emilie Soularue,[*] Lysiane Marthey,[*] and Franck Carbonnel[*,‡,||]

*Department of Gastroenterology, Kremlin Bicêtre Hospital, Assistance Publique-Hopitaux de Paris, Le Kremlin Bicêtre, France; ‡Paris Saclay University, Le Kremlin Bicêtre, France; §INSERM, U1193, Paul-Brousse University Hospital, Hepatobiliary Centre, Villejuif, France; ||INSERM 1018, UPS, UVSQ Institut Gustave Roussy, Villejuif Cedex, France

Immune checkpoint inhibitors (ICIs) have improved the treatment of several cancers. These drugs increase T-cell activity and the antitumor immune response but also have immune-related adverse effects that can affect the gastrointestinal (GI) tract. These adverse effects have been observed in 7% to 30% of patients treated with ICIs. As the number of diseases treated with ICIs increases, gastroenterologists will see more patients with ICI-induced GI adverse events. We performed a systematic review of the incidence, risk factors, clinical manifestations, and management of the adverse effects of ICIs on the GI tract. Treatment with anti–cytotoxic T-lymphocyte–associated

https://www.ema.europa.eu/en/medicines/human/EPAR/yervoy; https://www.ema.europa.eu/en/medicines/human/EPAR/keytruda; https://www.accessdata.fda.gov/drugsatfda_docs/label/2019/125554s070lbl.pdf; https://www.accessdata.fda.gov/drugsatfda_docs/label/2018/125377s094lbl.pdf; https://www.accessdata.fda.gov/drugsatfda_docs/label/2018/125514s034lbl.pdf). In contrast to the direct cytotoxic action of chemotherapy, ICIs enhance T-cell activity. This leads to a systemic loss of tolerance, with resulting antitumor efficacy but also immune-related adverse effects, involving most commonly the

Inflammatory Bowel Diseases, 2024, **30**, 1018–1031
https://doi.org/10.1093/ibd/izad229
Advance access publication 6 October 2023
Review Article - Translational

Focus on Immune Checkpoint Inhibitors-related Intestinal Inflammation: From Pathogenesis to Therapeutical Approach

Angelo Del Gaudio, MD, [*,†] Federica Di Vincenzo, MD, [*,†] Valentina Petito, MD, PhD, [*,†] Maria Cristina Giustiniani, MD, PhD, [‡] Antonio Gasbarrini, MD, PhD, [*,†] Franco Scaldaferri, MD, PhD, [*,†] and Loris Riccardo Lopetuso, MD, PhD[*,†,§,¶]

[*]From the [*]UOS Malattie Infiammatorie Croniche Intestinali, Centro di Malattie dell'Apparato Digerente (CEMAD), Fondazione Policlinico Universitario A. Gemelli IRCCS, Università Cattolica del Sacro Cuore, Roma, 00168, Italy
[†]UOC di Medicina Interna e Gastroenterologia, Dipartimento di Scienze Mediche e Chirurgiche, Fondazione Policlinico Universitario A. Gemelli IRCCS, Università Cattolica del Sacro Cuore, Roma, 00168, Italy
[‡]Department of Pathology, Fondazione Policlinico Universitario A. Gemelli IRCCS, Roma, 00168, Italy
[§]Department of Medicine and Ageing Sciences, G. d'Annunzio University of Chieti-Pescara, Chieti, 66100, Italy
[¶]Center for Advanced Studies and Technology (CAST), "G. d'Annunzio" University of Chieti-Pescara, Chieti, 66100, Italy

Downloaded from https://aca

World Journal of Gastroenterology

Submit a Manuscript: https://www.f6publishing.com

World J Gastroenterol 2021 May 28; 27(20): 2657-2663

DOI: 10.3748/wjg.v27.i20.2657

ISSN 1007-9327 (print) ISSN 2219-2840 (online)

CASE REPORT

Cyclophosphamide-associated enteritis presenting with severe protein-losing enteropathy in granulomatosis with polyangiitis: A case report

OPEN ACCESS PEER-REVIEWED CHAPTER

Drug-Related Enteropathy

WRITTEN BY

Octavio Gómez-Escudero

Submitted: 03 February 2022 , Reviewed: 15 February 2022 , Published: 25 March 2022

DOI: 10.5772/intechopen.103734



FROM THE EDITED VOLUME

Benign Anorectal Disorders - An Update

Edited by Alberto Vannelli and Daniela Cornelia Lazar

Book Details | Order Print

CHAPTER METRICS OVERVIEW

1,119 Chapter Downloads

View Full Metrics

REGISTER TO DOWNLOAD FOR FREE

Search UpToDate

Thanks for your attention

